

Mako[®] Partial Knee

Patellofemoral



**Mako
Robotic-Arm
Assisted Surgery**

Table of contents

Implant compatibility 3

Pre-operative implant planning 4

Intra-operative planning 5

Planning technique tips 8

Initial exposure and array placement 9

Bone registration and gap balancing 10

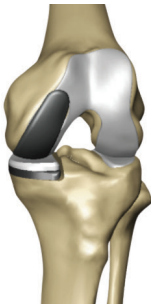Fine-tune implant positioning and bone resection 12

Trialing, soft tissue balancing and implant
insertion 13

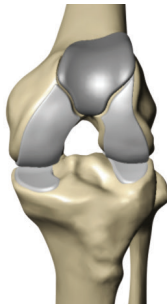
This publication sets forth detailed recommended procedures for using Stryker’s devices and instruments. It offers guidance that you should heed, but as with any such technical guide, each surgeon must consider the particular needs of each patient and make appropriate adjustments when and as required.

Note: the information provided in this document is not to be used as the surgical technique when completing a Mako Partial Knee procedure. Please refer to the Mako PKA Surgical Guide (PN 210713) for detailed intended use, contraindications, and other essential product information.

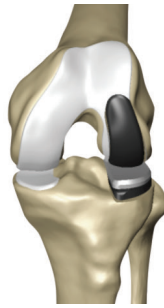Implant compatibility



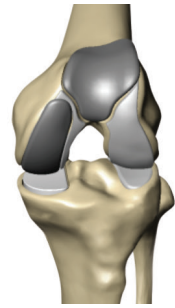Medial



Patellofemoral



Lateral



**Medial
bicompartimental**

Mako MCK Implant System

	Options	Sizes	Part number
Femoral implant	Left medial/Right lateral	1-8	18050X
	Right medial/Left lateral	1-8	18051X
Tibial baseplate	Left medial/Right lateral	1-8	18060X
	Right medial/Left lateral	1-8	18061X
Poly insert	8,9,10,12mm	1-8	18070X-X
X3 insert	8,9,10,12mm	1-8	18073X-X
Patella implant	3mm increments	26-41mm	180320-X
Patellofemoral implant	Left	2-8	18040X
	Right	2-8	18041X

Pre-operative implant planning

The goals of pre-operative implant planning are:

1. Size: Determine appropriate implant size
2. Fit: Define appropriate implant position and orientation

Implant size

In the quadrant of the computer screen showing the transverse view, select the largest patellofemoral (PF) component that does not overhang the bone in the medial and lateral direction. It should be no more than 2mm inset on either side (figure 1). Although the positioning

limits allow for internal rotation, the preferred setting is 0° internal, even for a prominent lateral trochlear ridge. In these conditions, the lateral edge of the component will be recessed into the bone (not proud of bone), which is acceptable (figure 2).

Note:

Use of 3 pre-set views of the patellofemoral component in the software application is recommended. Alternatively, the user may elect to manually scroll through the appropriate slices of the bone model to verify proper size and fit of the PF implant. Appendix 1 shows the anatomical planes in the 3 pre-set PF views.

Lateralizing the trochlear groove improves patella tracking. Externally rotating the patellofemoral component will lateralize the trochlear groove, but it will also decrease lateral patella jump height (decrease lateral patella constraint), and therefore is not recommended. Internally rotating the patellofemoral component will increase lateral patella jump height (increase lateral patella constraint), but it will also undesirably medialize the trochlear groove. Any internal rotation of the component should be accompanied by lateral translation to offset the medialization due to internal rotation.

Incorrect selection of the medial and lateral epicondyle CT landmarks will impact the internal/external rotation values, it is important to confirm these are correct.

Note:

Use of the “PF Primary” pre-set view can be very useful because the transverse plane of this view goes through the widest section of the component.

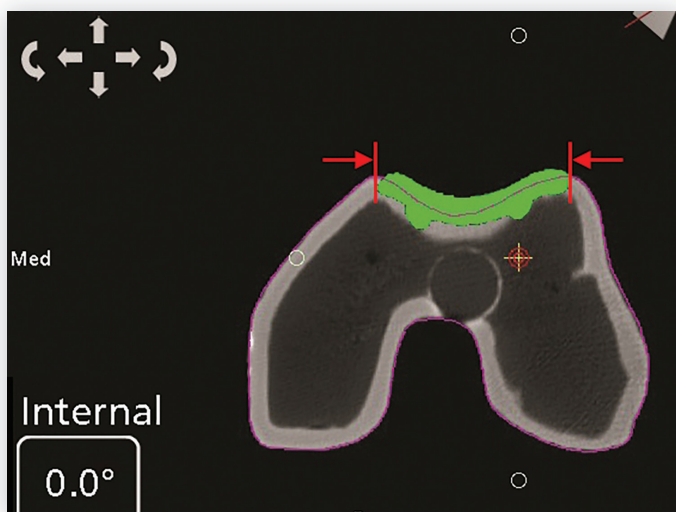


Figure 1

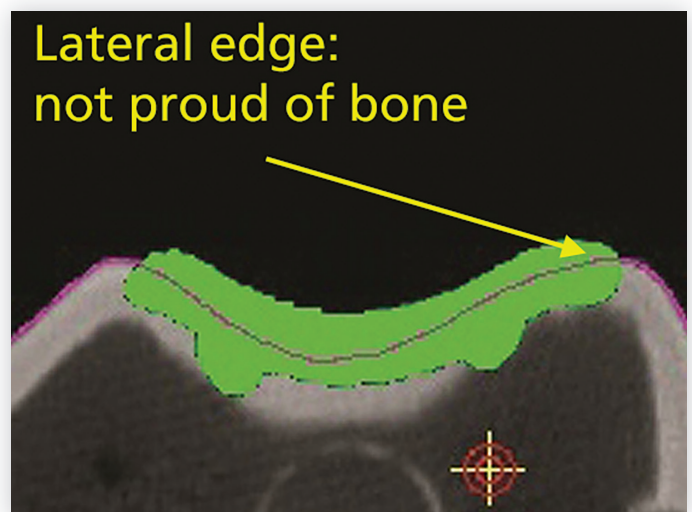


Figure 2

Implant fit overview

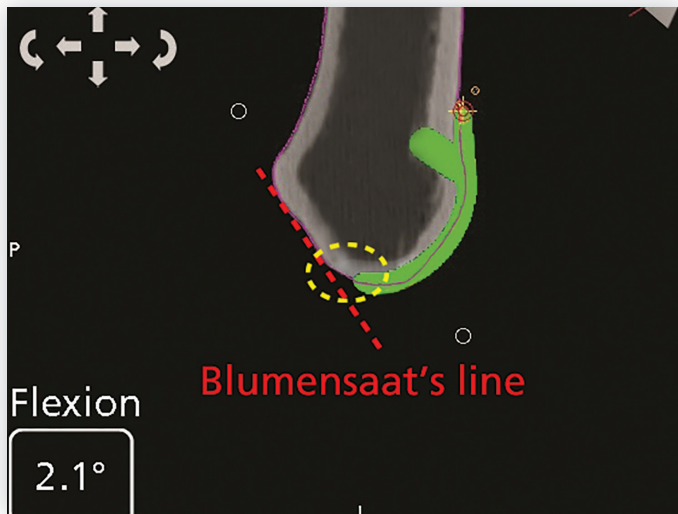


Figure 3

Scroll through the transverse slices of the bone model to ensure proper implant fit. Then, verify that in the sagittal quadrant the trochlear groove of the implant is 1-2mm proud (approximate thickness of healthy cartilage) of Whiteside's line, and that the distal tongue of the component does not interfere with the ACL. The distal tip of the component should be anterior to Blumensaat's line (figure 3). In the sagittal plane, the implant is 3mm thick superiorly and 4mm thick distally.

Note:

This can be accomplished using the "PF Verify 2" pre-set view in which the sagittal plane sections the implant through the deepest point of the trochlear groove.

Implant fit: Overview

An implant with proper fit meets the following requirements:

1. The superior-lateral edge of the anterior flange is split midway by bone, and the superior-medial edge of the anterior flange is at least contacting bone.
2. The component trochlear groove is 1-2mm proud of the bone trochlear groove.
3. The distal tongue is centered on the intercondylar notch.

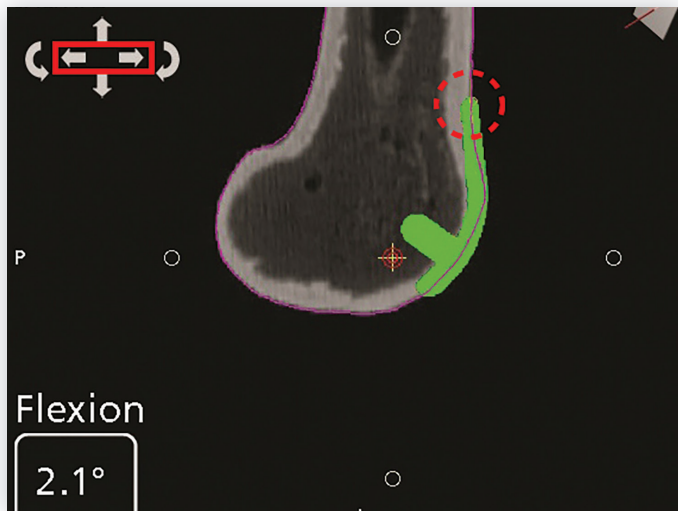

Figure 4

Implant fit: Details

1. In the sagittal view, adjust the component in the anterior/posterior dimension until the lateral edge of the anterior flange is split midway by bone (figure 4).

Note:

In the "PF Primary" pre-set view the sagittal plane crosses the implant through the superior-lateral edge. Similarly, in the "PF Verify 1" pre-set view the sagittal plane cuts the implant through the superior-medial edge. Use of "PF Primary" and "PF Verify 1" pre-set views to position the superior edges of the implant may expedite the process.

Implant fit overview

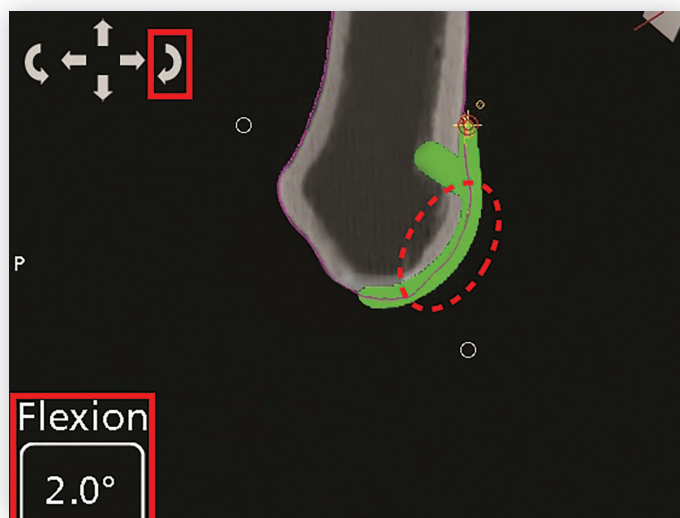

Figure 5

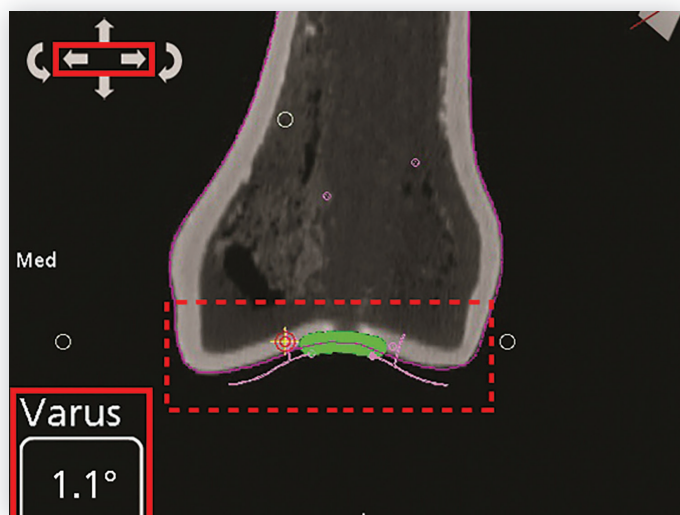


Figure 6

2. To fit the PF component 1-2mm proud of the trochlear groove bone, place the crosshair at the superior edge of the component to set the rotation anchor, manually scroll medially to the deepest point of the trochlear groove, and adjust flexion/extension until the implant is in the desired position. The preferred rotation value is 0-5° flexion (figure 5).

Note:

For this purpose, the sagittal quadrant of the “PF Verify 2” pre-set view can be useful. The sagittal plane of this pre-set view goes through the trochlear groove of the component.

3. In the coronal view, position the component so that it is centered on the notch, and its pink transition zones are 2mm proud of bone (approximate thickness of healthy cartilage). Adjust medial/lateral and varus/valgus as necessary (figure 6).

Note:

Placing the component in valgus will undesirably medialize the trochlear groove. Any valgus rotation should be accompanied by lateral translation to offset the medialization due to valgus rotation. If the component cannot be translated any more laterally, the preferred setting is 0-2° varus.

In both the “PF Primary” and “PF Verify 1” pre-set views, the coronal plane cuts the implant at the start of the distal tongue. Either of the two pre-set views can be used in this step.

Intra-operative planning

Confirmation of overall plan

Scroll through the slices of the bone model in all planes to verify proper implant fit, and that virtual implant position is in accordance to the recommended positioning limits.

The recommended positioning limit ranges are as follows:

- 4° internal to 0° external rotation; implant proud 1-2mm of bone at the trochlear groove (the preferred rotation is 0° external)
- 3° varus to 2° valgus; implant distal tongue center on the intercondylar notch (the preferred rotation is 0-2° varus)
- 5° flexion to 5° extension; from superior to inferior the bone line splits the implant (the preferred rotation is 0-5° flexion)

Intra-operative implant planning

The goals of intra-operative implant planning are:

1. Map cartilage surfaces

2. Fine-tune the implant position and orientation for proper implant proudness, and smooth transition from the component to the mapped cartilage surfaces

Cartilage mapping

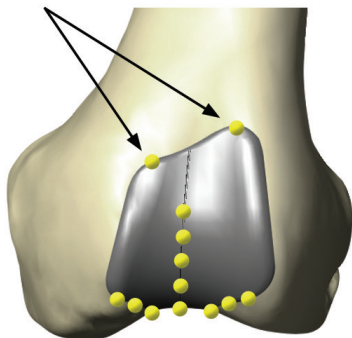
1. After bone registration is completed, use the green probe to collect points on the superior edges of the virtual component (one medial and one lateral).
2. Collect a minimum of five cartilage points along the deepest points of the trochlear groove (Whiteside's line).
3. Collect three cartilage points on each of the medial and lateral distal PF transition zones (Figure 7).

Note:

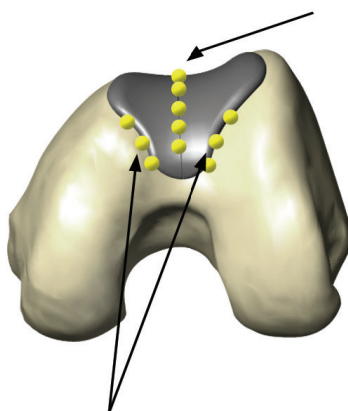
- **Collect points on the superior edges.**
- **Collect a minimum of five cartilage points.**
- **Collect three cartilage points on each lateral and medial PF transition zones.**

Patellofemoral (trochlear) intra-op cartilage mapping

1. Map 2 points at the medial and lateral superior edges



2. Map 5 cartilage points along the deepest point of the trochlear groove (most anterior to most distal)



3. Map 3 cartilage points along each of the medial and lateral transition zones

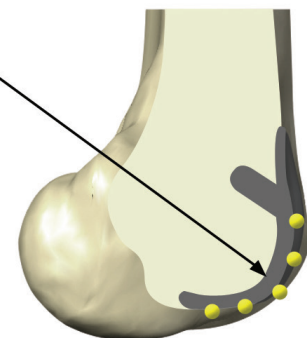
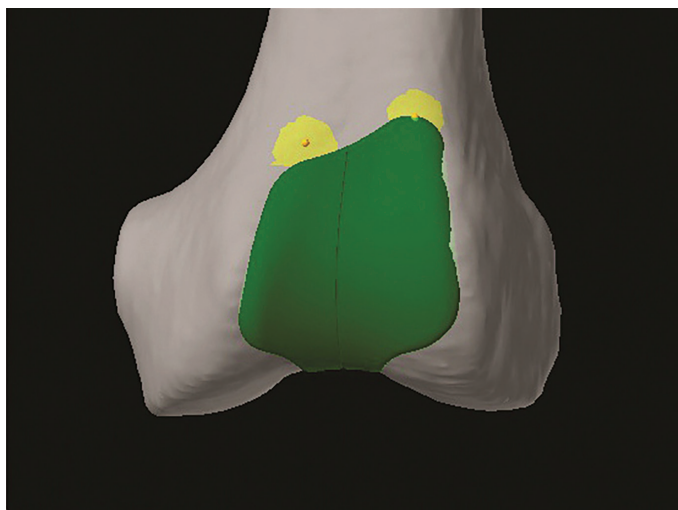

Figure 7

Fine-tune implant position



The cartilage surfaces mapped in the preceding section are now used to fine-tune the virtual implant position to ensure smooth transition from the implant to the cartilage. The areas of interest are:

1. Medial and lateral superior edges of the component
2. Trochlear groove
3. Medial and lateral distal transition zones from the component to the femoral condyles

Below are specific instructions on how to fine-tune and establish the final implant position.

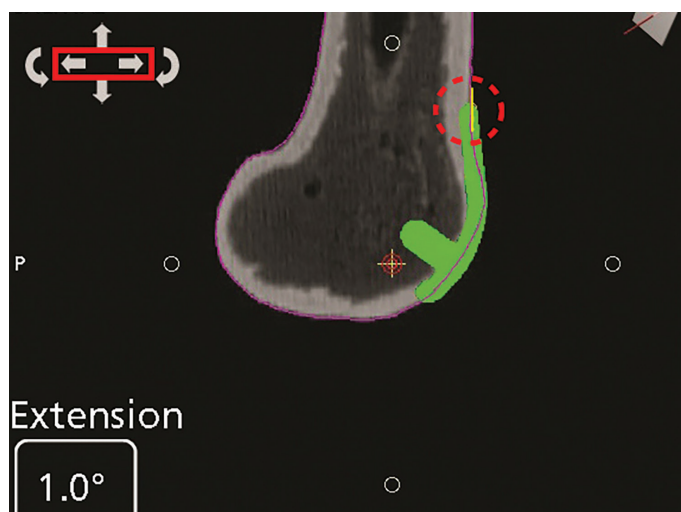

Figure 8

1. On the computer screen, the yellow surfaces (or lines) show the position of the mapped cartilage surface in proximity to the virtual implant. In the sagittal quadrant, translate the component in the anterior/posterior direction to ensure that the superior-lateral edge of the implant is placed midway through the mapped surface (figure 8). Verify that the superior-medial edge of the implant is contacting the medial mapped surface.
2. In the sagittal quadrant, the deepest point of the trochlear groove of the implant should rest on the cartilage mapped in the trochlear groove. To fine-tune, place the crosshair at the superior-lateral flange tip of the implant to set the rotation anchor, manually scroll to the deepest point of the trochlear groove, and adjust flexion/extension as required (figure 9a).

Note:

Use of the “PF Primary” and “PF Verify 1” pre-set views can save time in fine-tuning the position of the lateral and medial superior implant tips, respectively.

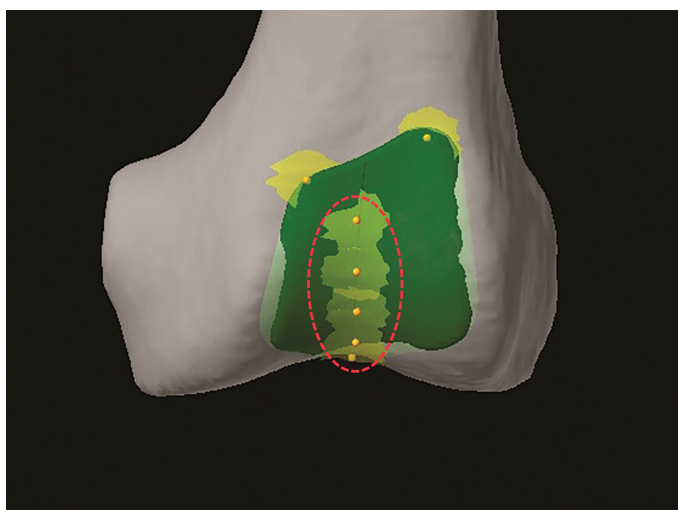


Figure 9a

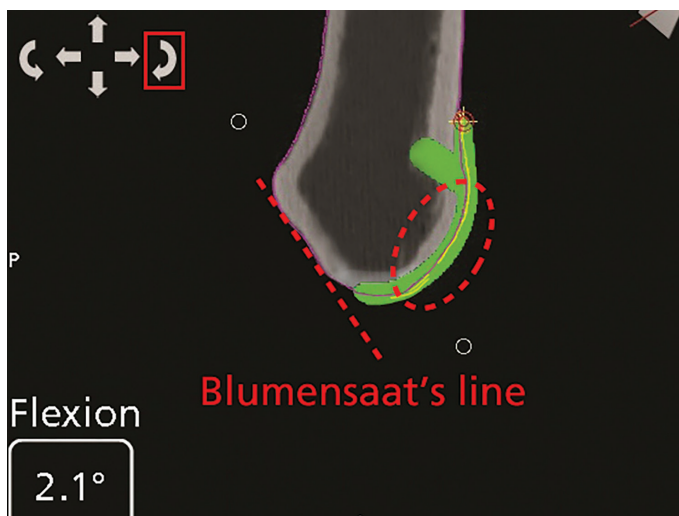


Figure 9b

In the same quadrant, verify that there is no interference with the ACL. The PF component should lie anteriorly to Blumensaat's line (Figure 9b).

3. Distally, in the sagittal and coronal quadrants, the virtual implant should be flush (or slightly recessed) to the cartilage. The mapped cartilage is represented as yellow lines. Adjust superior/inferior and varus/valgus of the implant to create a smooth transition from the distal-lateral edge of the component to the lateral cartilage of the femoral condyles. The preferred varus/valgus setting is 0-2° varus (figures 10, 11a and 11b).

Note:

By selecting the "PF Verify 2" pre-set view, the bone model is dissected in the sagittal plane right at the trochlear groove.

Use of the "PF Primary and PF Verify 1" pre-set views can be useful in fine-tuning the position of the component for smooth medial and lateral transition zones, respectively. "PF Primary" is useful for lateral and "PF Verify 1" for the medial transition zones.

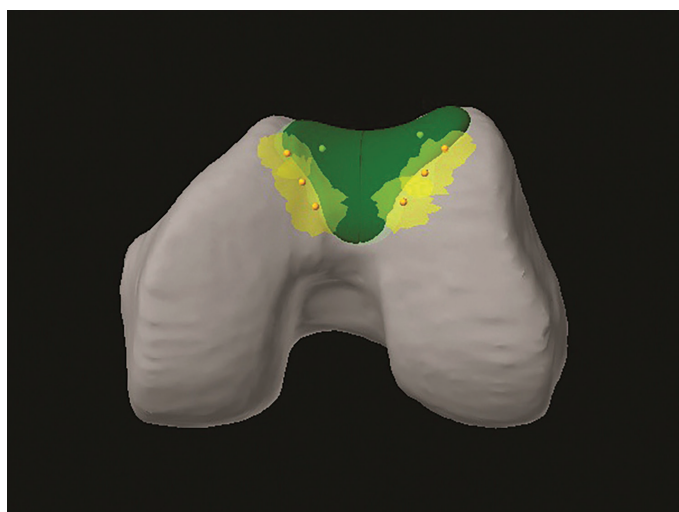


Figure 10

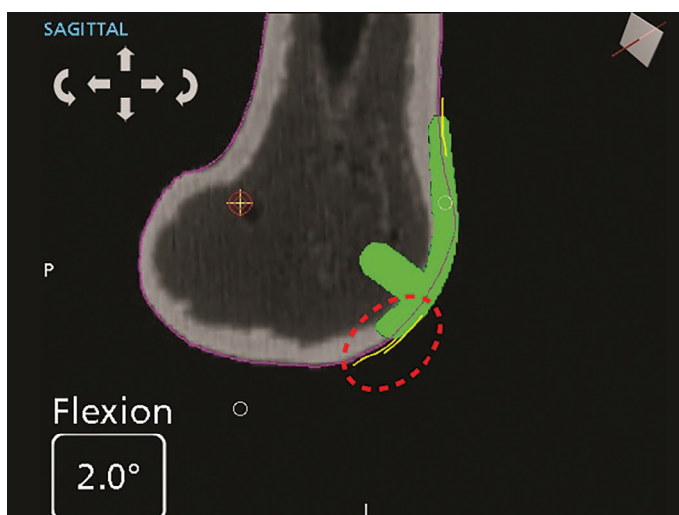


Figure 11a

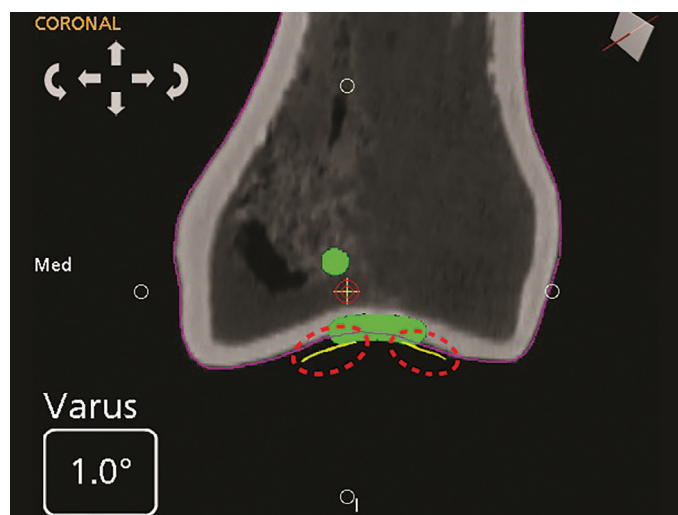


Figure 11b

Implant planning tips

Note:

Do not compromise fit on the lateral transition zone in favor of the medial transition zone. Since the patella tracks primarily laterally, the lateral transition zone is the most important, and the medial transition zone is secondary.

Removing the “pink transition zones” from the visual display helps avoid confusion with the yellow lines representing the mapped cartilage surfaces.

Planning tips

A. Occasionally it is difficult for the implant to perfectly match the anatomy. Below is the order of importance for the implant to match the mapped cartilage areas:

1. Trochlear groove and lateral femoral condyle transition zone
2. Medial femoral condyle transition zone
3. Superior (proximal) edges of component

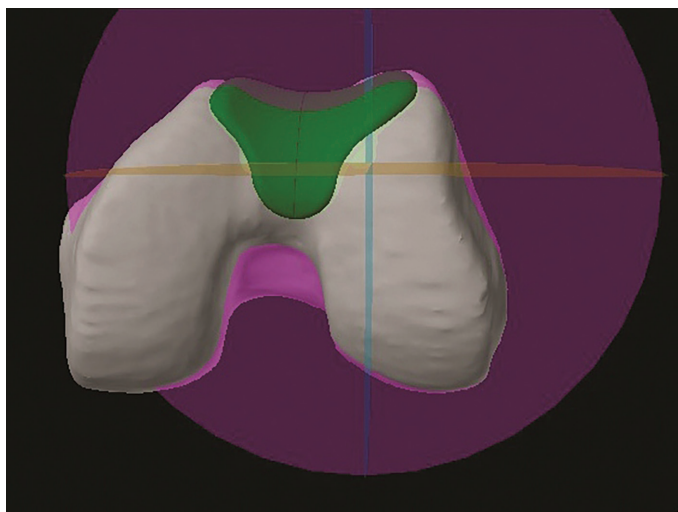
Matching the trochlear groove may help prevent overstuffing of the joint and allow for an anatomical reconstruction.

A smooth transition, particularly to the lateral femoral condyle, is very important for good kinematics and to help prevent clunking.

Contact between the patella and the superior section of the component occurs during full extension when there is little tension in the patellar tendon. Therefore, matching the superior areas is less important.

B. Patellofemoral joint overstuffing is one of the most common sources of anterior knee pain post-operatively. Proper procedure planning and careful execution allows for precise placement of the PF component. Anatomic resurfacing of the patella is also needed to ensure good kinematics. Exact reconstruction of the patella thickness and shape is as important as proper PF component placement. If the PF component must seat proud on the native trochlear groove, the thickness of the resurfaced patella may need to be adjusted (reduced) to prevent overstuffing.

A smooth transition, particularly to the lateral femoral condyle, is very important for good kinematics and to help prevent clunking.



Appendix - Pre-set PF views

PF Primary (figure A) – This pre-set view is the most useful because it is used to set size, as well as 5 out of the 6 degrees of freedom.

- Transverse plane: Sections the PF component through its widest medial/lateral extent. This is useful for setting size, medial/lateral position, and internal/external rotation.
- Coronal plane: Sections the PF component through the distal tongue (patella transition zone). This is useful for setting superior/inferior position and varus/valgus rotation.
- Sagittal plane: Sections the PF component through the most superior-lateral flange tip. This is useful for setting anterior/posterior position.

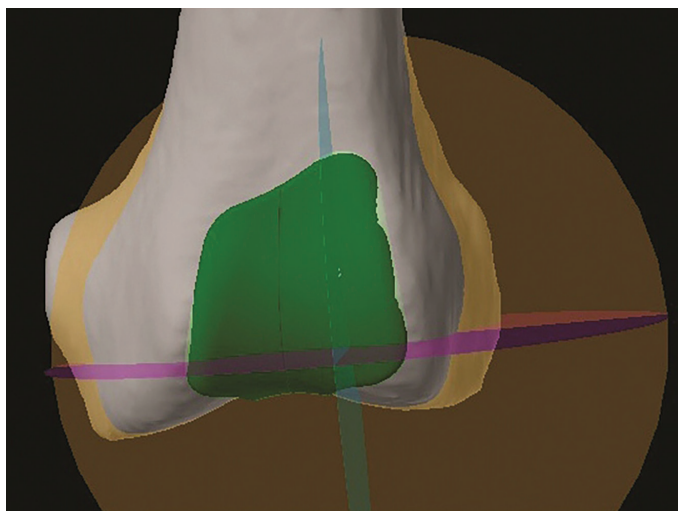
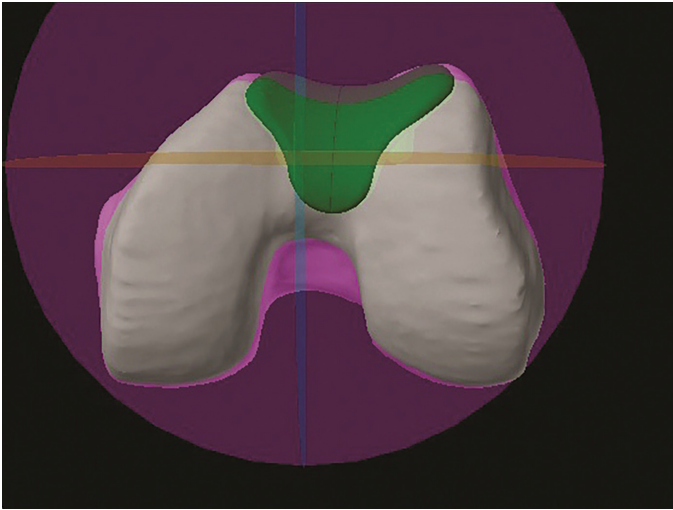


Figure A



PF Verify 1 (figure B) – This pre-set view is identical to PF Primary except that the sagittal plane sections through the superior-medial flange tip. It is used to verify that the superior-medial flange is contacting bone and that the patella transition is still good even if adjustments are made.

- Transverse plane: Sections the PF component through its widest medial/lateral extent. This is useful for verifying size, and medial/lateral position, and internal/external rotation.
- Coronal plane: Sections the PF component through the distal tongue (patella transition zone). This is useful for verifying superior/inferior position and varus/valgus rotation.
- Sagittal plane: Sections the PF component through the most superior-medial flange tip. This is useful for verifying anterior/posterior position.

Note:

This pre-set view is identical to PF Primary except that the sagittal plane sections through the superior-medial flange tip.

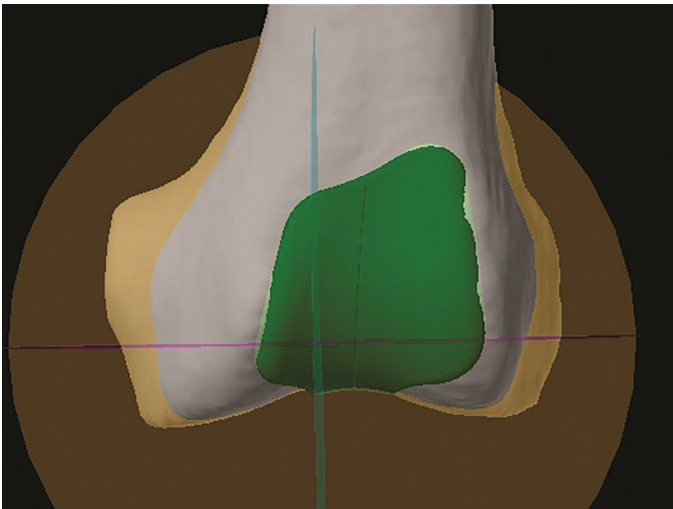
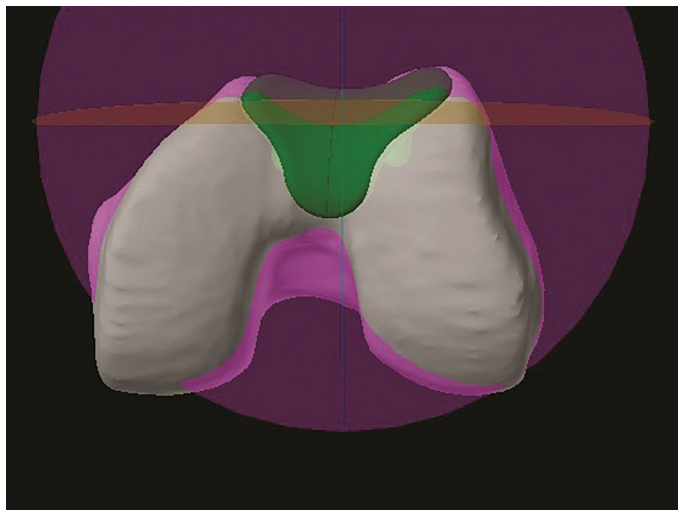


Figure B



PF Verify 2 (figure C) – This pre-set view is important for setting the depth of the PF trochlear groove to the bone trochlear groove, and to verify that the patella transition is still good even if adjustments were made.

- Transverse plane: Sections the PF component just inferior to the widest medial/lateral extent. This is useful for verifying patella transition.
- Coronal plane: Sections the PF component just anterior to the distal tongue (patella transition zone). This is useful for verifying patella transition.
- Sagittal plane: Sections the PF component through the deepest point of the trochlear groove. This is useful for setting flexion/extension rotation.

Note:

This pre-set view is important for setting the depth of the PF trochlear groove to the bone trochlear groove.

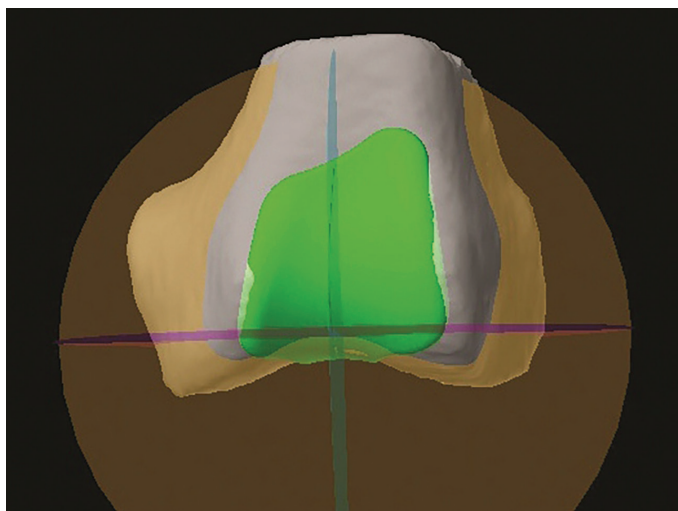


Figure C

Notes

Notes



325 Corporate Drive
Mahwah, NJ 07430
t: 201.831.5000

www.stryker.com

A surgeon must always rely on his or her own professional clinical judgment when deciding whether to use a particular product when treating a particular patient. Stryker does not dispense medical advice and recommends that surgeons be trained in the use of any particular product before using it in surgery.

The information presented is intended to demonstrate the breadth of Stryker's product offerings. A surgeon must always refer to the package insert, product label and/or instructions for use before using any of Stryker's products. The products depicted are CE marked according to the Medical Device Directive 93/42/EEC. Products may not be available in all markets because product availability is subject to the regulatory and/or medical practices in individual markets. Please contact your sales representative if you have questions about the availability of Stryker's products in your area. Stryker Corporation or its divisions or other corporate affiliated entities own, use or have applied for the following trademarks or service marks: Mako, Stryker.

All other trademarks are trademarks of their respective owners or holders.

MAKPKA-PG-4_Rev-1_16761 Copyright © 2019 Stryker.